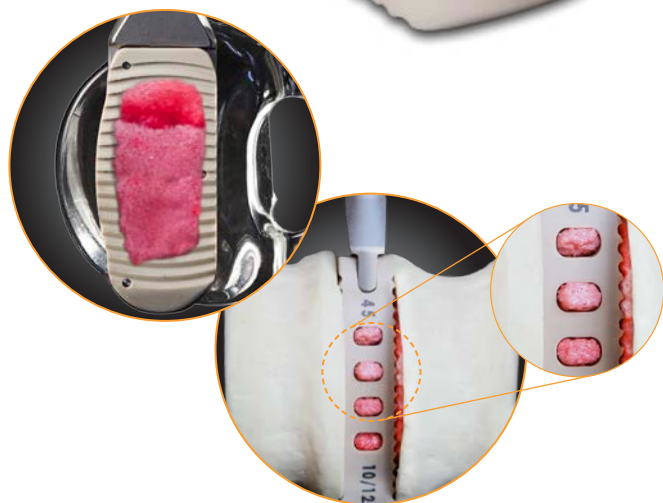



InFill® Lateral System

A novel technique for optimizing graft filling and endplate contact in lumbar interbody fusion surgery

Burak M. Ozgur MD FAANS^a

and

Erin Gleckman PA-C^b

Newport Beach, CA

^a Burak M. Ozgur MD FAANS. Founder/Director ONE Brain and Spine Center, Newport Beach, CA.

Chief of Neurosurgery Spine, Hoag Hospital, Newport Beach, CA.

^b Erin Gleckman PA-C. Physician Assistant to Burak Ozgur MD. Newport Beach, CA.

Abstract

Background

Lumbar spinal fusion has become a standard for spinal stabilization. Various techniques and approaches have evolved but all are predicated on fusion principles. Some of these principles include proper carpentry, discectomy, graft filling/packing, and endplate contact and fusion surface area.

Purpose

The purpose of this study is to evaluate the efficacy of a novel graft filling technique for maximizing interbody space and cage filling with optimizing graft endplate surface contact.

Methods

This pilot study was performed utilizing a full human cadaveric lumbar spine from T12-S1 and performing standard lateral approach discectomy and endplate preparation at four lumbar disc levels from L1-L5. Subsequently, standard lateral lumbar cages were inserted at each level pre-packed with standard graft material. Thin-cut CT scans with 3-D reconstructions were performed to demonstrate the standard cage and graft implantation with particular attention to volumetric analysis and endplate surface contact. The InFill lateral system technology was then utilized at each level to inject additional graft material into the interbody spaces and cages. CT imaging was repeated to attain comparison data for pre and post fill changes. Independent/clinically practicing radiologist made official CT scan reading of findings.

Results

At L1-L2, the pre and post injection graft volumes measured 3.038 and 5.115 cc respectively, demonstrating a change of 2.077 cc or an increase by 68%. At L2-L3, the pre and post injection graft volumes measured 3.136 and 5.376 cc respectively, demonstrating a change of 2.24 cc or an increase by 71%. At L3-L4, the pre and post injection graft volumes measured 3.584 and 4.836 cc respectively, demonstrating a change of 1.252 cc or an increase by 35%. At L4-L5, the pre and post injection graft volumes measured 3.528 and 6.851 cc respectively, demonstrating a change of 3.323 cc or an increase by 94%.

Conclusion

The results of this pilot study demonstrate successful increase in interbody space and cage filling with greatly enhanced endplate surface contact by utilizing this novel InFill technique. Volumetric analysis by 3-D CT scanning demonstrates a range of 35-94% increase depending on lumbar spine levels as well as improved graft endplate surface contour filling and contact. Published literature emphasizes the point that optimized interbody cage placement and graft filling with endplate surface contact apposition are all important elements directly correlated with successful fusion. Further studies and long-term fusion analysis will be supplementary, however thus far this study suggests this technique may enhance lumbar interbody fusion surgeries and outcome.

Introduction

Lumbar spine fusion has become one of the tools in surgical treatment of low back pain for the past few decades. Fusion has proven successful in treating many conditions of the lumbar spine that may cause low back pain including degenerative disc disease, facet arthropathy, adult degenerative scoliosis, instability and spondylolisthesis^{1,2}. Many different surgical approaches to lumbar spine fusion have been described including anterior, posterior and lateral approaches. Cappuccino A et al. report the biomechanical profile of each is determined by the extent of resection of local supportive structures, implant size and orientation, and the type of supplemental internal fixation used³.

There has been much variation in lumbar interbody fusion rates depending on the study, approach, cage and instrumentation. Radiographic outcomes in the study by Malham et al. were consistent with previously-reported results which showed fusion rate ranges between 91% and 100% with XLIF approach⁴. In the systematic review of fusion rates that Lee et al. performed, various studies on ALIF and PLIF approaches were reviewed and fusion rates varied depending on additional instrumentation ranging anywhere from 77%-95%⁵. Kim MC et al. found the fusion rate of TLIF in their study at the 2 year follow-up to be 95.4% which they reported was comparable to findings in other studies⁶. The overall fusion rate of stand-alone ALIF using the SynFix-LR system with BMP-2 was 90.6 %⁷. Marchi et al. in their study of lateral interbody fusion found that fusion was observed in 86.6% of the levels treated⁸.

In evaluating the efficacy of this novel graft filling technique, the InFill Lateral System demonstrates a successful increase in interbody space and cage filling with greatly enhanced endplate surface contact.

Researchers have found that stability and size of the cage plays a role in the success of spinal fusion⁹. Kim Y concluded in the study of bone and cage interface that it is likely that the larger the disc area or pedicle diameter, the more stable the interbody fusion of the spinal segments¹⁰. Wider cages have been found to create better surface area while reducing subsidence¹¹. Polikeit et al. concluded that cages should be designed to offer a large volume for interface between the bone and bone graft¹².

Endplate preparation is also important and removal of the central bony endplate for bone grafts has been noted to improve graft incorporation and has been recommended because it does not affect the compressive strength and promotes graft incorporation¹³. Endplates of the lumbar vertebrae are usually concave while most of the implants and cages are flat leaving a gap in surface area between the cage with graft and endplate¹⁴. We propose that an injectable graft material into the cage after implantation would create better contact with the endplate and cover more surface area to promote fusion and ultimately lead to faster fusion and higher fusion rates in the lumbar spine. This may lead to lower rates of pseudoarthrosis and improved patient outcomes.

Methods

This pilot study was performed utilizing a full human cadaveric lumbar spine from T12-S1 and performing standard lateral approach discectomy and endplate preparation at four lumbar disc levels from L1-L5. Various standard surgical tools were used to obtain maximal soft tissue removal including disc material and cartilaginous endplate yet preserving the bony endplates. Figure 1 demonstrates the cadaveric preparation.

Subsequently, standard lateral lumbar cages were inserted at each level pre-packed with standard graft material. Cages were manufactured by Pinnacle Spine and were standard 8/10(H) x 21(W) x 45(L) mm lordotic PEEK cages spacers. The manufacturer's volume (within the cage) is measured to be 3.4 cc. A drawing in Figure 2 demonstrates the cage and graft space. The cage has anterior 'vent' holes designed to allow graft/bone growth anteriorly. Calculating the space of the anterior vent holes takes the graft volume size to be 3.67 cc. This does not take into account the additional graft/bone growth that can take place superiorly and

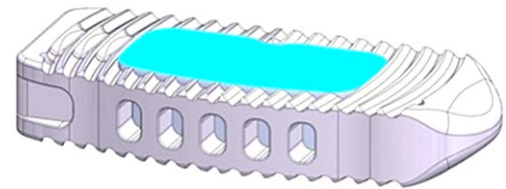


Figure 2: Drawing of the cage used and graft volume depicted.

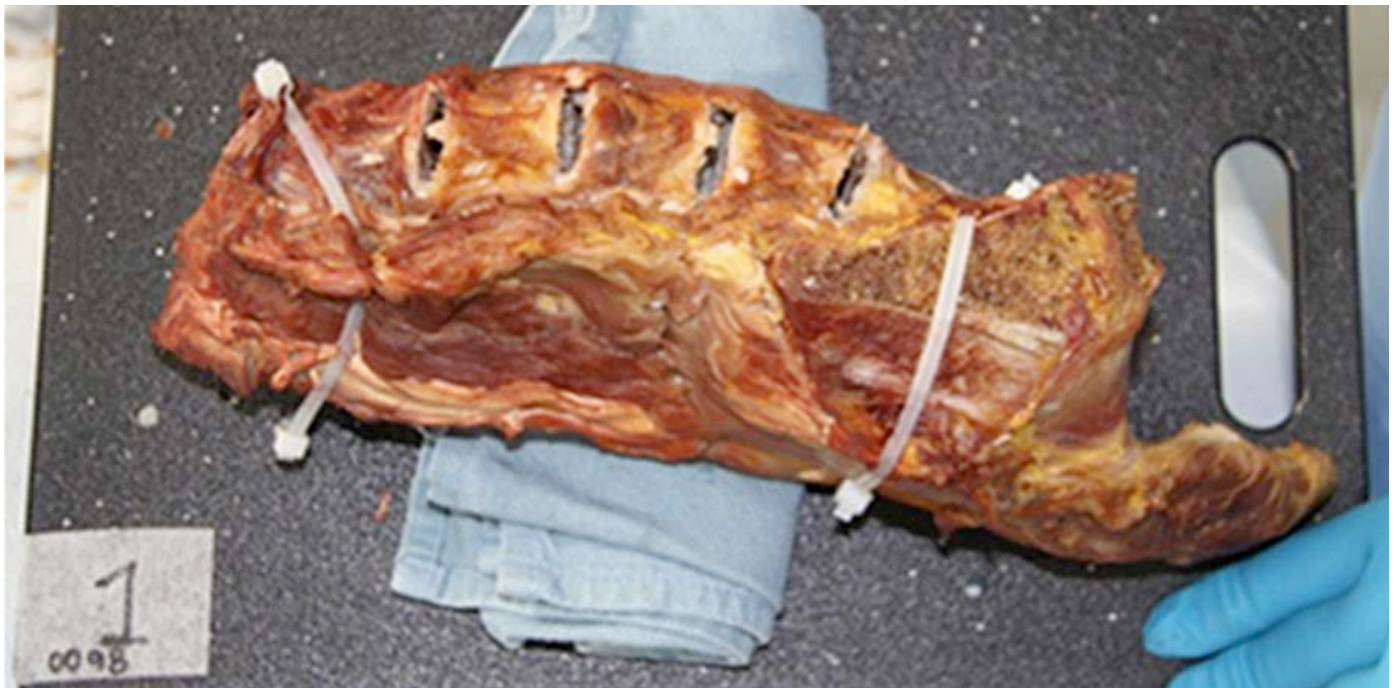

Figure 1: Picture of cadaver preparation following standard lateral approach discectomy.

inferiorly towards the endplates. The graft material used was a Calcium Phosphate Biomaterial manufactured by Etek mixed with Omnipaque for visualization purposes. 1.5cc of Omnipaque was mixed with 10 cc of the saline-hydrated graft material. The same graft/omnipaque mixture was 'injected' using the proprietary InFill technology after the initial imaging. It is of significant note that although cages were thoroughly packed prior to insertion, we observed that a significant amount of graft material falls out during insertion of the cage. This common phenomenon is demonstrated in Figure 3.

Thin-cut CT-scans (6 mm) with 3-D reconstructions were performed to demonstrate the standard cage and graft implantation with particular attention to volumetric analysis and endplate surface contact. The InFill lateral system technology was then utilized at each level to inject additional graft material into the interbody spaces and cages. CT imaging was repeated to attain comparison data for pre and post fill changes. Table 1 demonstrates the findings of the CT-scan report.

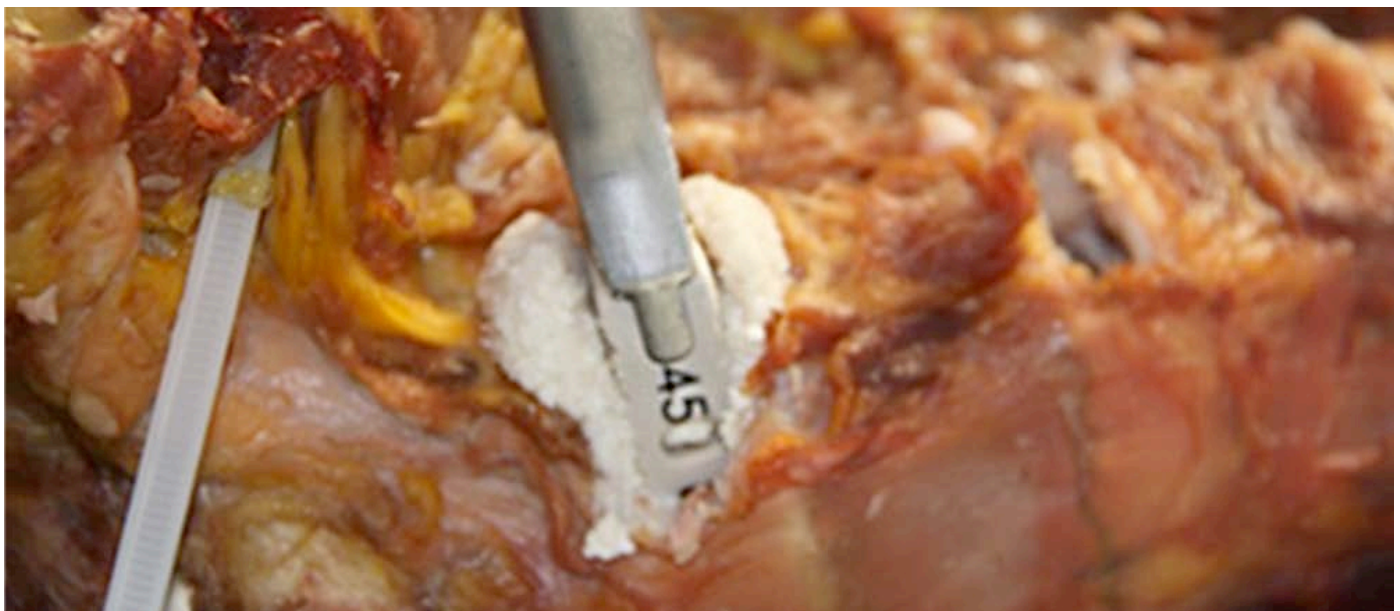

Figure 3: Picture of lateral cage and graft falling out during insertion.

Level	Pre InFill vol. (cc)	Post InFill vol. (cc)	Change in vol. (cc)	Increase
L1-L2	3.038	5.115	2.077	68%
L2-L3	3.136	5.376	2.240	71%
L3-L4	3.584	4.836	1.252	35%
L4-L5	3.528	6.851	3.323	94%

Table 1. Graft volumes and percentage change with InFill.

Results

The CT-scans were officially read out by a clinically practicing radiologist. These results are presented in Table 1. At L1-L2, the pre and post injection graft volumes measured 3.038 and 5.115 cc respectively, demonstrating a change of 2.077 cc or an increase by 68%. At L2-L3, the pre and post injection graft volumes measured 3.136 and 5.376 cc respectively, demonstrating a change of 2.24 cc or an increase by 71%. At L3-L4, the pre and post injection graft volumes measured 3.584 and 4.836 cc respectively, demonstrating a change of 1.252 cc or an increase by 35%. At L4-L5, the pre and post injection graft volumes measured 3.528 and 6.851 cc respectively, demonstrating a change of 3.323 cc or an increase by 94%.

Figures 4 and 5 demonstrate the sagittal 3-D images of the pre and post InFill injections of additional graft material respectively. Take particular notice of the dissipation of the gas/air space in the cage/endplate void in the pre Infill image (Figure 4). Also note the effective superior and inferior endplate opposition of graft as well as the proper depiction of concave endplate surface area contact demonstrated in the post InFill image (Figure 5).

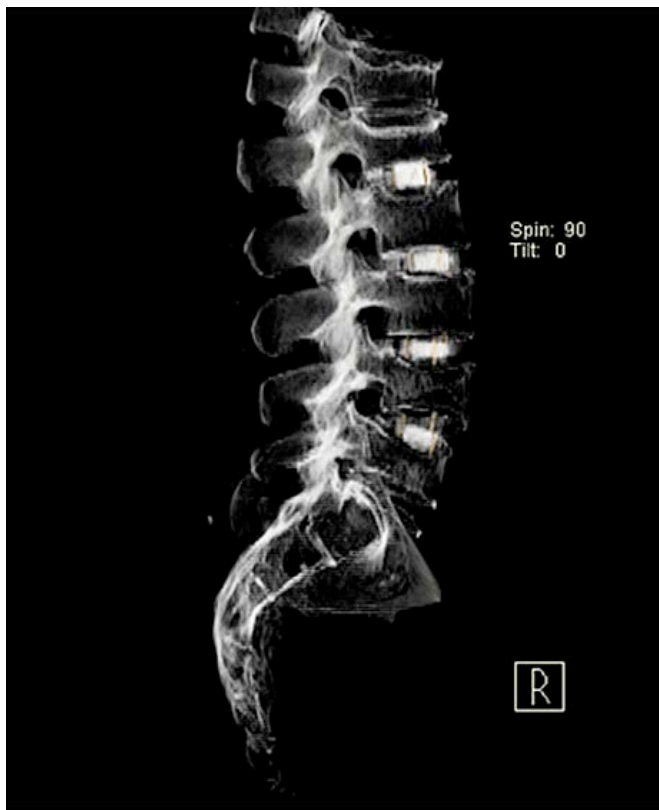


Figure 4: 3-D CT-scan image of pre Infill injection of graft material.

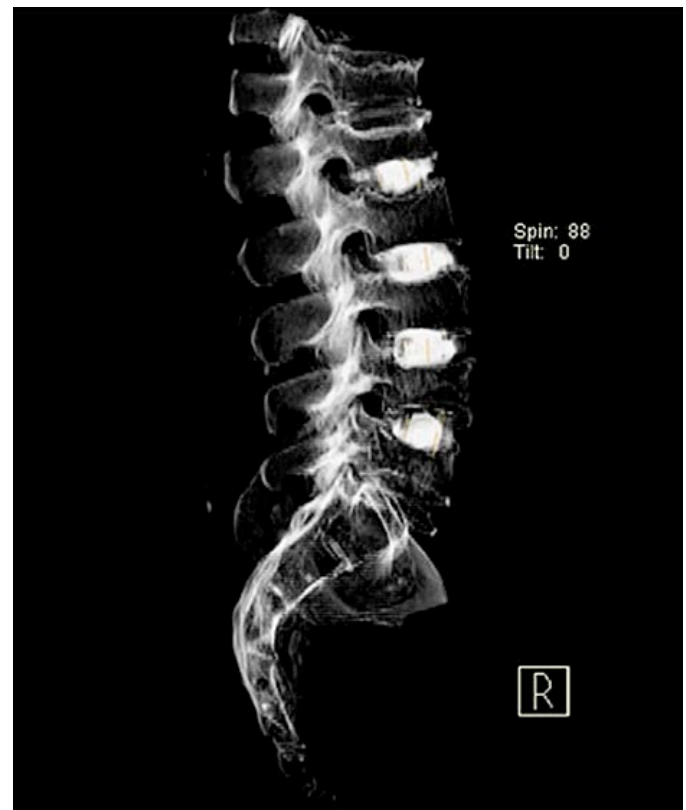

Figure 5: 3-D CT-scan image of post Infill injection of graft material.

Conclusion

Lumbar spinal stabilization and fusion has become a critical part of the armamentarium of the spine surgeon. We have always accepted the importance of classic and basic principles of complete discectomy, proper endplate preparation and cage packing. However, it has been increasingly important to analyze our outcomes in terms of successful fusions, rates of pseudoarthrosis, and costs in the changing healthcare-economic climate. The purpose of this study was to try and quantify the properties of cage packing, graft insertion, and potential benefits of additional graft packing post-insertion. The results of this pilot study demonstrate successful increase in interbody space and cage filling with greatly enhanced endplate surface contact by utilizing this novel InFill technique. Volumetric analysis by 3-D CT scanning demonstrates a range of 35-94% increase depending on lumbar spine levels as well as improved graft endplate surface contour filling and contact. Published literature emphasizes the point that optimized interbody cage placement and graft filling with endplate surface contact apposition are all important elements directly correlated with successful fusion. Jun BY quotes "successful arthrodesis in posterior lumbar interbody fusion requires both a large amount of graft and maximal graft filling"¹⁵. Additionally, Pumberger et al. emphasized that maximal structural graft or implant coverage of the endplates are of critical importance for fusion¹⁶. This pilot study demonstrates definitively that this InFill technology can aid in improving graft filling and attaining better space filling with endplate coverage and surface area contact. Additional work may demonstrate that this finding will then yield better fusion results and perhaps more efficiency in interbody space packing and cost effective use of graft materials, bone void fillers, and recombinant DNA technologies. Further studies and long-term fusion analysis will be supplementary, however thus far this study suggests this technique may enhance lumbar interbody fusion surgeries and outcome.

Volumetric analysis by 3-D CT scanning demonstrates a range of 39-94% increase in interbody space and cage filling with the InFill Lateral system, as well as improved graft endplate surface contour filling and contact.

Bibliography

1. Kaner T, Sasani M, Oktenoglu T, Ozer AF. Dynamic stabilization of the spine: a new classification system. *Turk Neurosurg.* 2010;20(2):205-215.
2. Panjabi MM. Clinical spinal instability and low back pain. *J Electromyogr Kinesiol.* 2003;13(4):371-379.
3. Cappuccino A, Cornwall GB, Turner AW, et al. Biomechanical analysis and review of lateral lumbar fusion constructs. *Spine (Phila Pa 1976).* 2010;35 (26 Suppl):S361-367.
4. Malham GM, Ellis NJ, Parker RM, Seex KA. Clinical outcome and fusion rates after the first 30 extreme lateral interbody fusions. *ScientificWorldJournal.* 2012;2012:246989.
5. Lee CS, Hwang CJ, Lee DH, Kim YT, Lee HS. Fusion rates of instrumented lumbar spinal arthrodesis according to surgical approach: a systematic review of randomized trials. *Clin Orthop Surg.* 2011;3(1):39-47.
6. Kim MC, Chung HT, Kim DJ, Kim SH, Jeon SH. The clinical and radiological outcomes of minimally invasive transforaminal lumbar interbody single level fusion. *Asian Spine J.* 2011;5(2):111-116.
7. Behrbalk E, Uri O, Parks RM, Musson R, Soh RC, Boszczyk BM. Fusion and subsidence rate of stand alone anterior lumbar interbody fusion using PEEK cage with recombinant human bone morphogenetic protein-2. *Eur Spine J.* 2013.
8. Marchi L, Abdala N, Oliveira L, Amaral R, Coutinho E, Pimenta L. Stand-alone lateral interbody fusion for the treatment of low-grade degenerative spondylolisthesis. *ScientificWorldJournal.* 2012;2012:456346.
9. Le Huec JC, Liu M, Skalli W, Josse L. Lumbar lateral interbody cage with plate augmentation: in vitro biomechanical analysis. *Eur Spine J.* 2002;11(2):130-136.
10. Kim Y. Prediction of mechanical behaviors at interfaces between bone and two interbody cages of lumbar spine segments. *Spine (Phila Pa 1976).* 2001;26(13):1437-1442.
11. Subach BR, Copay AG, Martin MM, Schuler TC. Anterior lumbar interbody implants: importance of the interdevice distance. *Adv Orthop.* 2011;2011:176497.
12. Polikeit A, Ferguson SJ, Nolte LP, Orr TE. The importance of the endplate for interbody cages in the lumbar spine. *Eur Spine J.* 2003;12(6):556-561.
13. Steffen T, Tsantrizos A, Aebi M. Effect of implant design and endplate preparation on the compressive strength of interbody fusion constructs. *Spine (Phila Pa 1976).* 2000;25(9):1077-1084.
14. Lakshmanan P, Purushothaman B, Dvorak V, Schratz W, Thambiraj S, Boszczyk M. Sagittal endplate morphology of the lower lumbar spine. *Eur Spine J.* 2012;21 Suppl 2:S160-164.
15. Jun BY. Posterior lumbar interbody fusion with restoration of lamina and facet fusion. *Spine (Phila Pa 1976).* 2000;25(8):917-922.
16. Pumberger M, Gogia J, Hughes AP, Kotwal SY, Girardi FP, Sama AA. Conventional manual discectomy versus powered discectomy for interbody fusion in the lumbar spine: cadaveric testing in forty levels. *J Spinal Disord Tech.* 2011;24(8):E71-74.